Original Article

Morphological Variation of Mandibular Molars in Rohilkhand Population: An Original Research

Tanu Singh[1], Saurav Bathla[2], Saurav Kumar Dutta[2], Minhaj Ahmed Amer Mohammed[3], Navdeep Jethi[4], Harsh Chansoria[5], Saraswathi Sravani Pulluri[6]

[1]PhD Scholar, Faculty of Dental Sciences, Department of Conservative Dentistry and Endodontics, Bareilly International University, Bareilly, Uttar Pradesh, India, [2]Post Graduate Student, Department of Conservative Dentistry and Endodontics, Institute of Dental Sciences, Bareilly, Uttar Pradesh, India, [3]Department of Oral and Maxillofacial Surgery, NIMS Dental College and Hospital, NIMS University, Jaipur, Rajasthan, India, [4]Department of Conservative Dentistry and Endodontics, Daswani Dental College and Research Centre, Kota, Rajasthan, India, [5]Department of Prosthodontics Crown and Bridge, Govt. College of Dentistry Indore, Madhya Pradesh, India, [6]Department of Health Information Technology, University of Maryland, Baltimore County, Baltimore

Abstract

Introduction: In-depth knowledge of common and aberrant pulp morphology is essential for appropriate diagnosis and treatment planning before commencing root canal treatment. The radicular morphology of mandibular molars has been extensively studied. Considerable variation in the number of canals and roots found in these teeth has been reported. **Aim:** The purpose of this study is to investigate the root canal morphology of the mandibular molars among the Rohilkhand population using Dentascan. **Materials and Methods:** Dentascan images of mandibular molar were taken from 99 extracted teeth that were collected from the Department of Oral Surgery and Maxillofacial Surgery, Institute of Dental Sciences, Bareilly, and private clinics. The examination of root canal systems of the teeth was based on Vertucci's classification. **Results:** The mandibular molar (n = 99) were taken. Out of the 99 teeth examined, three canals were seen in 60 (60.6%) teeth, four canals in 39 (39.4%) teeth, 3% had extra distal roots, and 6% with C-shaped canals. **Conclusion:** Among mandibular first molars, only 3% had three roots. Mesial roots of the first molar typically present with two canals and two apical foramina with type IV or II canal configuration. Most distal roots of the first molar presented with a type I canal configuration. The remainder were distributed mainly between types II, IV, III, and V. Among 99 mandibular molars, 6% had single C-shaped roots.

Keywords: *Morphology, permanent mandibular molars, root canal*

Submitted: 16-Sep-2023
Revised: 27-Sep-2023
Accepted: 22-Oct-2023
Published: 29-Feb-2024

Introduction

Knowledge of the common and aberrant varying pulp morphologies is essential for an appropriate diagnosis and treatment plan before commencing root canal treatment (RCT). Appreciating the complexity of the root canal system and modifying the treatment protocol based on these individual root canal systems, establish the roadmap to aid in establishing successful endodontics for difficult cases.[1-4]

Studies on the radicular morphology of the mandibular molars have shown that there is a considerable variation in the number of canals and roots found in these teeth as reported by. Typically, the mandibular first molar has

Access this article online

Quick Response Code:

Website: https://journals.lww.com/jpbs

DOI: 10.4103/jpbs.jpbs_907_23

Address for correspondence: Dr. Saurav Bathla, Post Graduate Student, Department of Conservative Dentistry and Endodontics, Institute of Dental Sciences, Bareilly, Uttar Pradesh- 243006, India.
E-mail: saurav.bathla@yahoo.com

How to cite this article: Singh T, Bathla S, Dutta SK, Ahmed Amer Mohammed M, Jethi N, Chansoria H, *et al*. Morphological variation of mandibular molars in Rohilkhand population: An original research. J Pharm Bioall Sci 2024;16:S632-6.

two roots. One or three-rooted varieties have also been noticed, although uncommon.[4-8]

The root canal system and its morphological variations have been classified by several investigators. The most widely used is Vertucci's classification where he classified the root canal configuration into eight categories: Type I (1), Type II (2-1), Type III (1-2-1), Type IV (2), Type V (1-2), Type VI (2-1-2), Type VII (1-2-1-2), and Type VIII (Vertucci, 1984).[8-11] The internal dental anatomy is mostly studied using tooth clearing, sectioning, radiography (Zillich and Dowson, 1973), *in vitro* endodontic access through radiographs and instruments, *in vitro* macroscopic examination, and *in vitro* RCT with magnification.

Clinical examination and conventional periapical radiography are traditional methods to identify roots and root canals. However, they are complicated, time-consuming, and could result in sample destruction. Computed tomography (CT) and Dentascan, micro-CT (mCT), have been used to evaluate the root canal anatomy in a three-dimensional (3D) orientation because of the high resolution and nondestruction of the specimen.[11-15] CBCT and dental scan technique have become successful method for studying root canal anatomy as it is as precise as root canal staining and clearing techniques, which were used in the past since they are superior to conventional techniques because of their ability to produce a nondestructive 3D views and complete morphological details. To the best of our knowledge, limited study has so far evaluated the root canal morphology of mandibular molar in the Rohilkhand population using Dentascan. Therefore, this study aimed to investigate the root canal morphologies of the mandibular molars in a Rohilkhand region population using Dentascan.[15-19]

Materials and Methods

Ninety-nine mandibular permanent molars were used in this study. Teeth were collected from patients who came for extractions needed for several reasons such as caries or prosthodontic or orthodontic treatments at the Department of Oral Surgery and Maxillofacial Surgery, Institute of Dental Sciences, Bareilly and private clinics of Rohilkhand region. An informed-consent protocol approved by the Ethics Committee of Bareilly International University and conforming to the provisions of the Declaration of Helsinki of 1995 (as revised in Edinburgh 2000).

Teeth were washed immediately after extraction and stored in 10% formalin until the collection was completed. They were then boiled in 5% NaOH for 5 min and cleaned with 10% NaOCl for 40 min in a supersonic cleaner to remove organic debris on the surface. Any further deposits such as calculus and bone fragments were removed by scaling and polishing.

The Dentascan was taken operating at 90 kV and 87.5 mAs. The size of the field of view was selected depending on the requirements, and the number and type of root canals were recorded. During the evaluation of the samples, Vertucci's classification was used as the main reference. Vertucci's classified root canal configuration of human permanent teeth into eight types [Figure 1]: type 1 (1), a single canal extends from the pulp chamber to the apex; type II (2-1), two separate canals leave the pulp chamber and join short of the apex to form one canal; type III (1-2-1), one canal leaves the pulp chamber, divides into two within the root, and then merges to exit as one canal; type IV (2), two separate and distinct canals extend from the pulp chamber to the apex; type V (1-2), one canal leaves the pulp chamber and divides short of the apex into two separate and distinct canals with separate apical foramina; type VI (2-1-2), two separate canals leave the pulp chamber, merge within the body of the root, and redivide short of the apex to exit as two distinct canals; type VII (1-2-1-2), one canal leaves the pulp chamber, divides and then rejoins within the body of the root, and finally redivide into two distinct canals short of the apex; and type VIII (3), three separate canals extend from the pulp chamber to the apex. Aberrant forms of root canals that did not fit Vertucci's classification were also evaluated.[19-21]

Table 1: Root Number and Morphology of Rohilkhand Region Population Mandibular Molars

Root shape and number	M (*n*=99)
Three separate roots	3
Two separate roots	93
Single C-shaped root	3

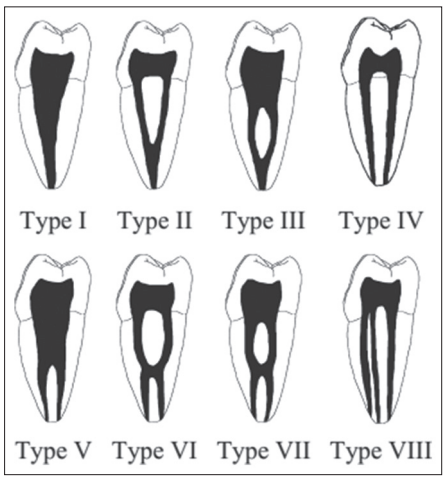

Figure 1: Vertucci's Classification

Table 2: Number of root canals in mesial root

	Number of root canals in the mesial root		
Tooth	One canal *n* (%)	Two canals *n* (%)	Total *n* (%)
1	0 (0%)	9 (100) %	9 (100%)
2	0 (0%)	9 (100) %	9 (100%)
3	0 (0%)	9 (100) %	9 (100%)
4	0 (0%)	9 (100) %	9 (100%)
5	0 (0%)	9 (100) %	9 (100%)
6	0 (0%)	9 (100) %	9 (100%)
7	0 (0%)	9 (100) %	9 (100%)
8	0 (0%)	9 (100) %	9 (100%)
9	0 (0%)	9 (100) %	9 (100%)
10	0 (0%)	9 (100) %	9 (100%)
11	0 (0%)	9 (100) %	9 (100%)
Total	0 (0%)	99 (100) %	99 (100) %

Table 3: Number of root canals in the distal root

	Number of root canals in the distal root		
Tooth	One canal *n* (%)	Two canals *n* (%)	Total *n* (%)
1	2 (22.2%)	7 (77.8) %	9 (100%)
2	1 (11.1%)	8 (88.9) %	9 (100%)
3	4 (44.4%)	5 (55.6) %	9 (100%)
4	6 (66.7%)	3 (33.3) %	9 (100%)
5	6 (66.7%)	3 (33.3) %	9 (100%)
6	7 (77.8%)	2 (22.2) %	9 (100%)
7	6 (66.7%)	3 (33.3) %	9 (100%)
8	7 (77.8%)	2 (22.2) %	9 (100%)
9	8 (88.9%)	1 (11.1) %	9 (100%)
10	8 (88.9%)	1 (11.1) %	9 (100%)
11	5 (55.6%)	4 (44.4) %	9 (100%)
Total	60 (60.6%)	39 (39.4%)	99 (100) %

Results

The data for root and canal morphology is presented in Tables 1–5, Figure 2. Out of the 99 mandibular first molars, only 3% had three roots, with the extra root lingual to the main distal root [Table 1]. The mesial roots typically presented with two canals and two apical foramina with type IV (82.8%) and II (17.2%) canal configurations [Tables 2 and 4]. Most of the distal roots presented with type I canal configuration (53.5%). The remainder was distributed mainly between types II (25.3%) and V (4%) [Tables 3 and 5].

Of the 99 molars, 6% had single C-shaped roots [Table 1].

Discussion

The methods used to study root canal morphology are replication technique,[3,8] clearing technique,[6,7, 9-14] use of radiopaque dyes and radiographs,[2,15-19] sectioning of teeth,[20] and recently, Dentascan, spiral computed tomography (SCT)[5] and cone beam computed tomography (CBCT).[21] A Dentascan examination is a specialized type of computed tomography study (CT or "CAT" scan), which is performed on a conventional CT scanner, which is used to obtain true cross sections of the mandible and maxilla from the easily obtained CT scans of the patients. The Dentascan formats standard axial CT scans into three planes: axial,(coronal) panoramic, and oblique sagittal (or cross-sectional) imaging.[4]

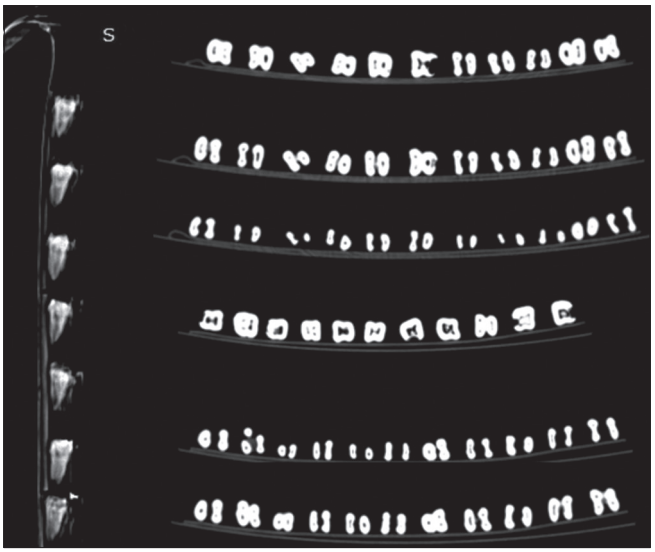

Figure 2: Dentascan images of mandibular molars

In this study, it was found that 39.4% of mandibular molars had four canals. These results are similar to those of Hartwell and Bellizzi,[17] who reported 35.1% of teeth and had four canals. This value is lower than the findings of several earlier authors,[13,14,19,21] but higher than that reported by Skidmore and Bjorndal,[3] Zaatar *et al*.,[18] Sperber and Moreau,[20] Gulabivala *et al*.,[7] and Reuben *et al*.[5] Owing to the high percentage of two distal canals, classical triangular access preparation during root canal treatment should be extended toward the distolingual direction in a rectangular form to improve canal identification.

In the mesial root, type IV configuration was most prevalent (82.8%) followed by type II (17.2%) configuration. This is consistent with the findings of most of the earlier studies,[3,6,7,11-14,16,20] except the studies by Zaatar *et al*.[18] and Al-Nazhan,[19] which reported type II being the most prevalent followed by type IV. In the present study, one mesial root showed an additional configuration type (2-1-2-1) as described by Gulabivala *et al*.[7] There are published reports indicating the presence of type VIII configuration in the mesial root, with an incidence of 0.2% to 5%.[6,7,11-14] However, in the present study, none of the samples had three canals in the mesial root.

Table 4: Root canal type of mesial root of mandibular molars in rohillkhand region, type of canal configuration

	Type of canal configuration									
Tooth	I *n* (%)	II *n* (%)	III *n* (%)	IV *n* (%)	V *n* (%)	VI *n* (%)	VII *n* (%)	VIII *n* (%)	XI *n* (%)	Total *n* (%)
1	0 (0%)	3 (33.3%)	0 (0%)	6 (66.7%)	0 (0%)	0 (0%)	0 (0%)	0 (0%)	0 (0%)	9 (100%)
2	0 (0%)	3 (33.3%)	0 (0%)	6 (66.7%)	0 (0%)	0 (0%)	0 (0%)	0 (0%)	0 (0%)	9 (100%)
3	0 (0%)	3 (33.3%)	0 (0%)	6 (66.7%)	0 (0%)	0 (0%)	0 (0%)	0 (0%)	0 (0%)	9 (100%)
4	0 (0%)	1 (11.1%)	0 (0%)	8 (88.9%)	0 (0%)	0 (0%)	0 (0%)	0 (0%)	0 (0%)	9 (100%)
5	0 (0%)	1 (11.1%)	0 (0%)	8 (88.9%)	0 (0%)	0 (0%)	0 (0%)	0 (0%)	0 (0%)	9 (100%)
6	0 (0%)	0 (0%)	0 (0%)	9 (100%)	0 (0%)	0 (0%)	0 (0%)	0 (0%)	0 (0%)	9 (100%)
7	0 (0%)	0 (0%)	0 (0%)	9 (100%)	0 (0%)	0 (0%)	0 (0%)	0 (0%)	0 (0%)	9 (100%)
8	0 (0%)	0 (0%)	0 (0%)	9 (100%)	0 (0%)	0 (0%)	0 (0%)	0 (0%)	0 (0%)	9 (100%)
9	0 (0%)	1 (11.1%)	0 (0%)	8 (88.9%)	0 (0%)	0 (0%)	0 (0%)	0 (0%)	0 (0%)	9 (100%)
10	0 (0%)	2 (22.2%)	0 (0%)	7 (77.8%)	0 (0%)	0 (0%)	0 (0%)	0 (0%)	0 (0%)	9 (100%)
11	0 (0%)	3 (33.3%)	0 (0%)	6 (66.7%)	0 (0%)	0 (0%)	0 (0%)	0 (0%)	0 (0%)	9 (100%)
Total	0 (0%)	17 (17.2%)	0 (0%)	82 (82.8%)	0 (0%)	0 (0%)	0 (0%)	0 (0%)	0 (0%)	99 (100%)

Table 5: Root canal type of distal root of mandibular molars in rohillkhand region, type of canal configuration

	Type of canal configuration									
Tooth	I *n* (%)	II *n* (%)	III *n* (%)	IV *n* (%)	V *n* (%)	VI *n* (%)	VII *n* (%)	VIII *n* (%)	XI *n* (%)	Total *n* (%)
1	1 (11.1%)	4 (44.4%)	1 (11.1%)	3 (33.3%)	0 (0%)	0 (0%)	0 (0%)	0 (0%)	0 (0%)	9 (100%)
2	1 (11.1%)	5 (55.6%)	0 (0%)	2 (22.2%)	1 (11.1%)	0 (0%)	0 (0%)	0 (0%)	0 (0%)	9 (100%)
3	3 (33.3%)	5 (55.6%)	1 (11.1%)	0 (0%)	0 (0%)	0 (0%)	0 (0%)	0 (0%)	0 (0%)	9 (100%)
4	5 (55.6%)	3 (33.3%)	1 (11.1%)	0 (0%)	0 (0%)	0 (0%)	0 (0%)	0 (0%)	0 (0%)	9 (100%)
5	5 (55.6%)	2 (22.2%)	1 (11.1%)	1 (11.1%)	0 (0%)	0 (0%)	0 (0%)	0 (0%)	0 (0%)	9 (100%)
6	6 (66.7%)	2 (22.2%)	1 (11.1%)	0 (0%)	0 (0%)	0 (0%)	0 (0%)	0 (0%)	0 (0%)	9 (100%)
7	5 (55.6%)	2 (22.2%)	1 (11.1%)	1 (11.1%)	0 (0%)	0 (0%)	0 (0%)	0 (0%)	0 (0%)	9 (100%)
8	6 (66.7%)	1 (11.1%)	1 (11.1%)	1 (11.1%)	0 (0%)	0 (0%)	0 (0%)	0 (0%)	0 (0%)	9 (100%)
9	8 (88.9%)	0 (0%)	0 (0%)	0 (0%)	1 (11.1%)	0 (0%)	0 (0%)	0 (0%)	0 (0%)	9 (100%)
10	8 (88.9%)	0 (0%)	0 (0%)	1 (11.1%)	0 (0%)	0 (0%)	0 (0%)	0 (0%)	0 (0%)	9 (100%)
11	5 (55.6%)	1 (11.1%)	0 (0%)	1 (11.1%)	2 (22.2%)	0 (0%)	0 (0%)	0 (0%)	0 (0%)	9 (100%)
Total	53 (53.5%)	25 (25.3%)	7 (7.1%)	10 (10.1%)	4 (4.0%)	0 (0%)	0 (0%)	0 (0%)	0 (0%)	99 (100%)

The most prevalent configuration in the distal root was type I (53.5%) followed by type II (25.3%), type IV (10.1%), type III (7.1%), and type V (4%) configuration. In terms of type II and type IV configuration, this figure is lower than the studies of Caliskan *et al*.,[11] Ahmed *et al*.,[11] and AlNazhan,[19] but higher than that reported by Skidmore and Bjorndal,[3] Vertucci,[6] Gulabivala *et al*.,[7] and Pineda and Kuttler.[16] The external morphology of the distal root is more rounded than the mesial one and therefore less likely to accommodate two separates continuous with the large main passage, is usually amenable to adequate enlarging and filling procedure, the preparation and filling of the other canal is often extremely difficult.[1] In the three rooted molars, all distolingual roots possessed type I (100%) canal configuration canals.

As compared with Dentascan, the newer CBCT (cone beam computed tomography) technology is much more cost-effective. CBCT also has reduced hindrance, restricting its routine use. Though Dentascan is expensive, recently, in-expensive X-ray tubes, decreased complexity, high-quality flat panel detector systems and powerful personal computers have made this technique more affordable and practical, in routine dental practice and a natural fit in imaging. However, no study, to the best of our knowledge, has evaluated mandibular molar root canal variations in the Rohilkhand population.

Lingeshwar *et al*.,[21] stated that CT scan was one of the upcoming diagnostic modalities in dentistry. A review article written on Dentascan, also stated that unlike previous imaging techniques, the oblique sagittal view of Dentascan permitted the evaluation of distinct buccal and lingual cortical bone margins, as well as clear visualization of internal structures, such as the incisive and inferior alveolar canals.

Thus, within the limitations of this study, it can be concluded that though Dentascan is a novel technique that has successfully been proven time and again by various *in vitro* studies, still, further, clinical studies are still required to prove its reliability and accuracy, before it can be used rationally and routinely practice. Better technique like CBCT imaging is a useful tool for assessing root and canal anatomy and may assist

endodontic specialists in making a diagnosis and planning further treatment.

Conclusions

The root canal morphology of 99 Rohilkhand population mandibular permanent molars shows higher incidence of four canals (39.4%) and extra distal roots (3%). Therefore, the clinician must always look for a second canal in the distal root of Indian mandibular first molars. The most prevalent canal configuration in the mesial root was Vertucci's type IV (82.8%), and in distal root type I (53.5%). An additional configuration, Gulabivala type (2-1-2-1), was found as a rare entity (0.6%) in mesial root. Variations in the number of roots or canals and teeth with unusual root canal configurations have a definite impact on treatment. To achieve long-term success, clinician must use all the armamentaria at their disposal to locate and treat the entire root canal system.

Financial support and sponsorship

Nil.

Conflicts of interest

There are no conflicts of interest.

References

1. Vertucci FJ. Root canal anatomy of the human permanent teeth. Oral Surg Oral Med Oral Pathol 1984;58:589-99.
2. Garg AK, Tewari RK, Kumar A, Hashmi SH, Agrawal N, Mishra SK. Prevalence of three-rooted mandibular permanent first molars among the Indian Population. J Endod 2010;36:1302-6.
3. Skidmore AE, Bjorndal AM. Root canal morphology of the human mandibular first molar. Oral Surg Oral Med Oral Pathol 1971;32:778-84.
4. Vandenberghe B, Jacobs R, Yang J. Detection of periodontal bone loss using digital intraoral and cone beam computed tomography images: An *in vitro* assessment of bony and/or infrabony defects. Dentomaxillofac Radiol 2008;37:252-60.
5. Reuben J, Velmurugan N, Kandaswamy D. The evaluation of root canal morphology of the mandibular first molar in an Indian population using spiral computed tomography scan: An *in vitro* study. J Endod 2008;34:212-5.
6. Neelakantan P, Subbarao C, Subbarao CV, Ravindranath M. Root and canal morphology of mandibular second molars in an Indian population. J Endod 2010;36:1319-22.
7. Gulabivala K, Opasanon A, Ng YL, Alavi A. Root and canal morphology of Thai mandibular molars. Int Endod J 2002;35:56-62.
8. Davis SR, Brayton SM, Goldman M. The morphology of the prepared root canal: A study utilizing injectable silicone. Oral Surg Oral Med Oral Pathol 1972;34:642-8.
9. Robertson D, Leeb IJ, McKee M, Brewer E. A clearing technique for the study of root canal systems. J Endod 1980;6:421-4.
10. Hasselgren G, Nellestam P, Bynum-Hasselgren RM. Teeth with transparent roots--an improved teaching aid for preclinical endodontics. J Endod 1987;13:126-7.
11. Calişkan MK, Pehlivan Y, Sepetçioğlu F, Türkün M, Tuncer SS. Root canal morphology of human permanent teeth in a Turkish population. J Endod 1995;21:200-4.
12. Ahmed HA, Abu-bakr NH, Yahia NA, Ibrahim YE. Root and canal morphology of permanent mandibular molars in a Sudanese population. Int Endod J 2007;40:766-71.
13. Chen YC, Lee YY, Pai SF, Yang SF. The morphologic characteristics of the distolingual roots of mandibular first molars in a Taiwanese population. J Endod 2009;35:643-5.
14. Al-Qudah AA, Awawdeh LA. Root and canal morphology of mandibular first and second molar teeth in a Jordanian population. Int Endod J 2009;42:775-84.
15. de Souza-Freitas JA, Lopes ES, Casati-Alvares L. Anatomic variations of lower first permanent molar roots in two ethnic groups. Oral Surg Oral Med Oral Pathol 1971;31:274-8.
16. Pineda F, Kuttler Y. Mesiodistal and buccolingual roentgenographic investigation of 7,275 root canals. Oral Surg Oral Med Oral Pathol 1972;33:101-10.
17. Hartwell G, Bellizzi R. Clinical investigation of *in vivo* endodontically treated mandibular and maxillary molars. J Endod 1982;8:555-7.
18. Zaatar EI, al Anizi SA, al Duwairi Y. A study of the dental pulp cavity of mandibular first permanent molars in the Kuwaiti population. J Endod 1998;24:125-7.
19. al-Nazhan S. Incidence of four canals in root-canal-treated mandibular first molars in a Saudi Arabian sub-population. Int Endod J 1999;32:49-52.
20. Sperber GH, Moreau JL. Study of the number of roots and canals in Senegalese first permanent mandibular molars. Int Endod J 1998;31:117-22.
21. Lingeshwar D, Dhanasekar B, Aparna IN. Diagnostic imaging in implant dentistry. Int J Oral Implantol Clin Res 2010;1:147-53.